阑尾切除术的局解手术学

安徽医科大学人体解剖学教研室

目的与要求

- 了解阑尾的解剖形态特点。
- 掌握阑尾切除术的层次关系及重要结构。
- 掌握阑尾切除术的步骤及注意事项。
- 熟悉实验小论文的书写格式和方法。

（一）腹前壁的层次关系

层次：由浅→深

- 皮肤
- 浅筋膜
- 深筋膜
- 腹前外侧肌
- 腹横筋膜
- 腹膜下筋膜
- 壁腹膜

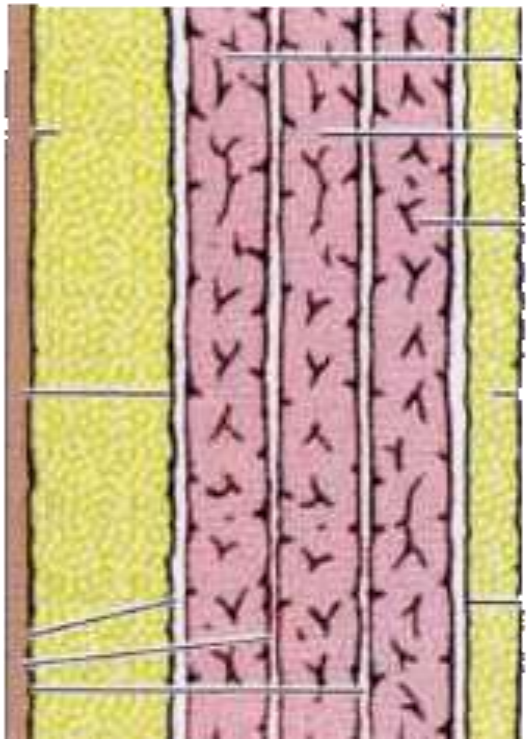

1、皮肤

- 薄、富有弹性
- 与皮下组织连接疏松

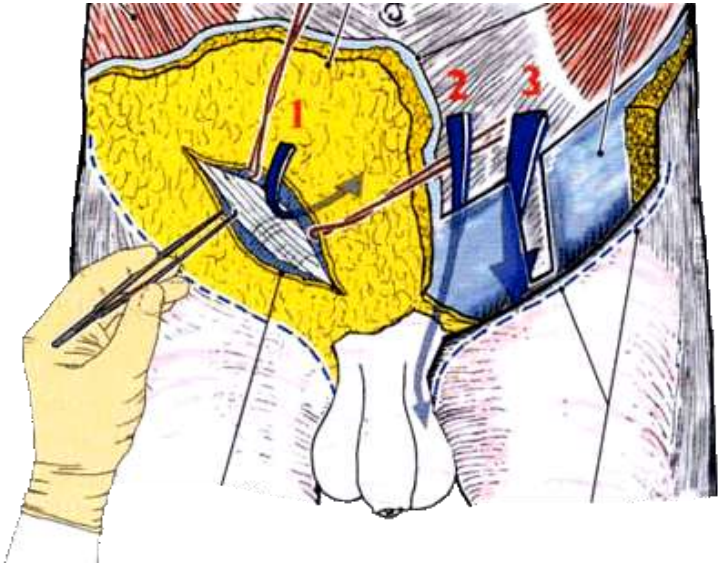

2、浅筋膜

- Camper 筋膜
- Scarpa 筋膜

3、深筋膜

- 薄、不完整，与腹部大幅度的伸缩有关
- 不单独作为一层

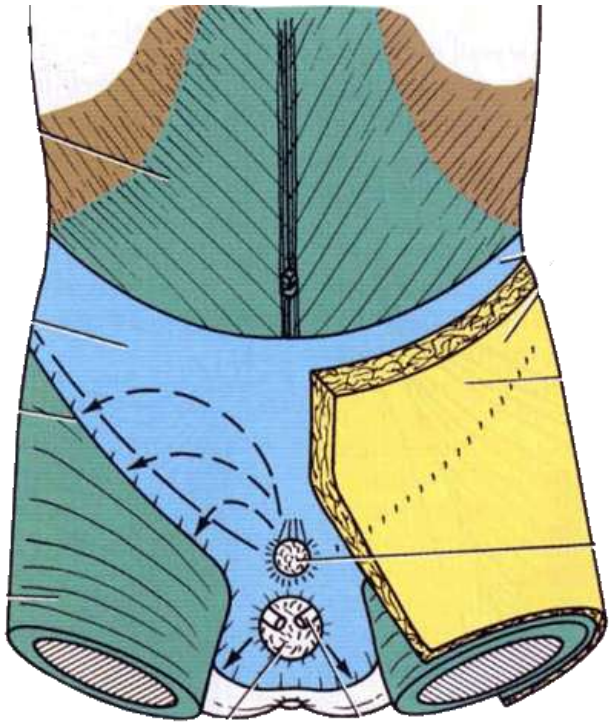

4、腹外侧群肌

- 腹外斜肌
- 腹内斜肌
- 腹横肌

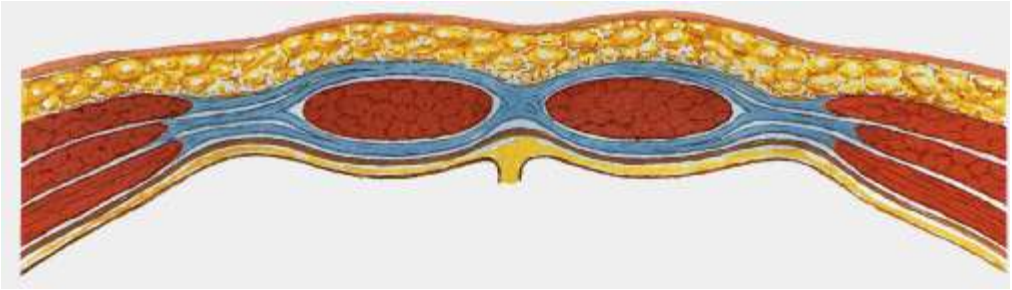

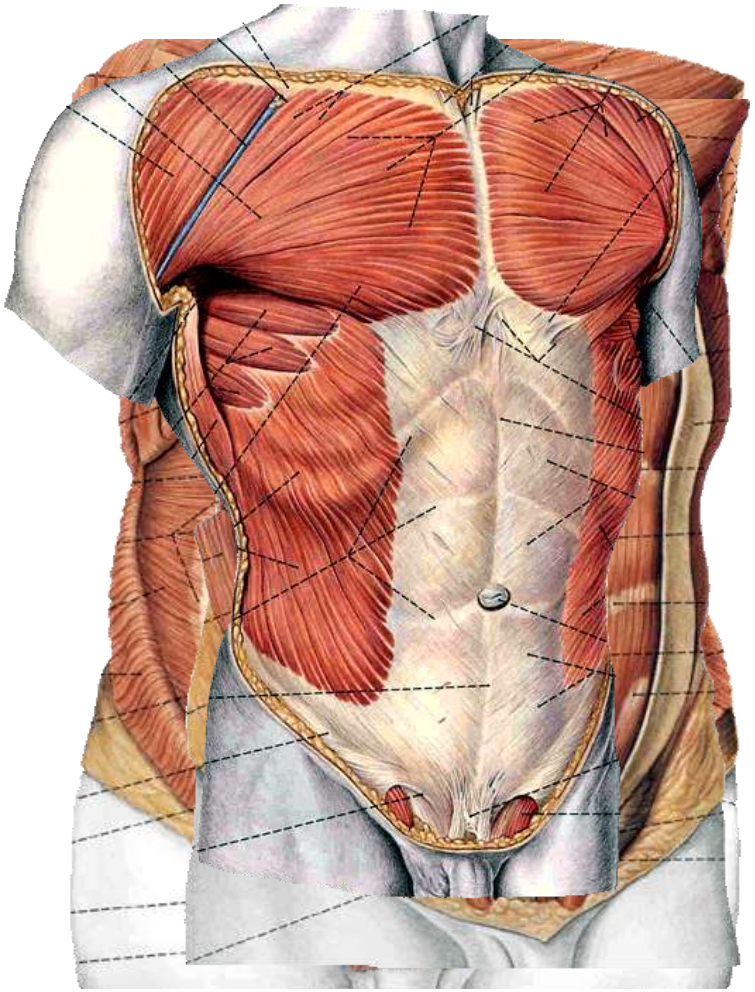

腹外斜肌形成结构

- 腹股沟韧带
- 腹股沟浅环

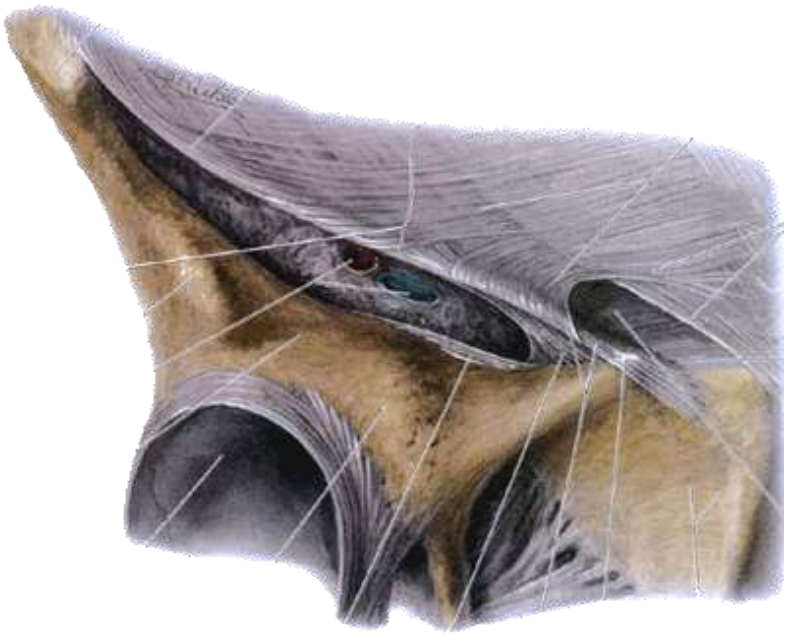

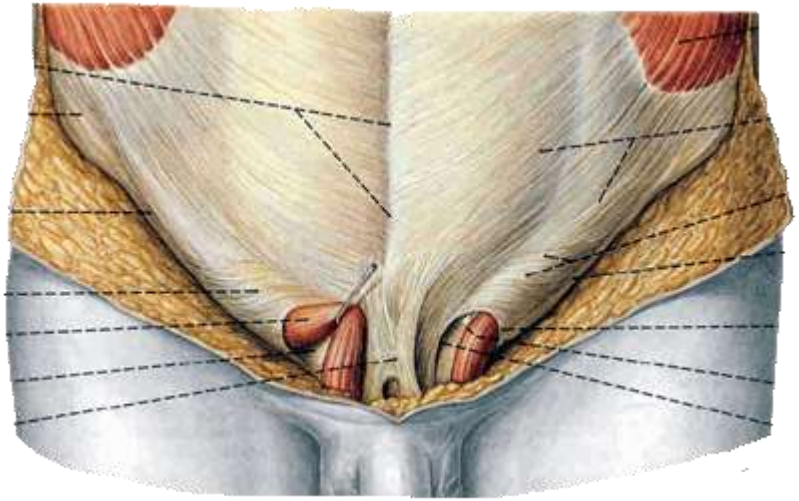

腹内斜肌及腹横肌形成结构

- 腹股沟镰
- 提睾丸肌

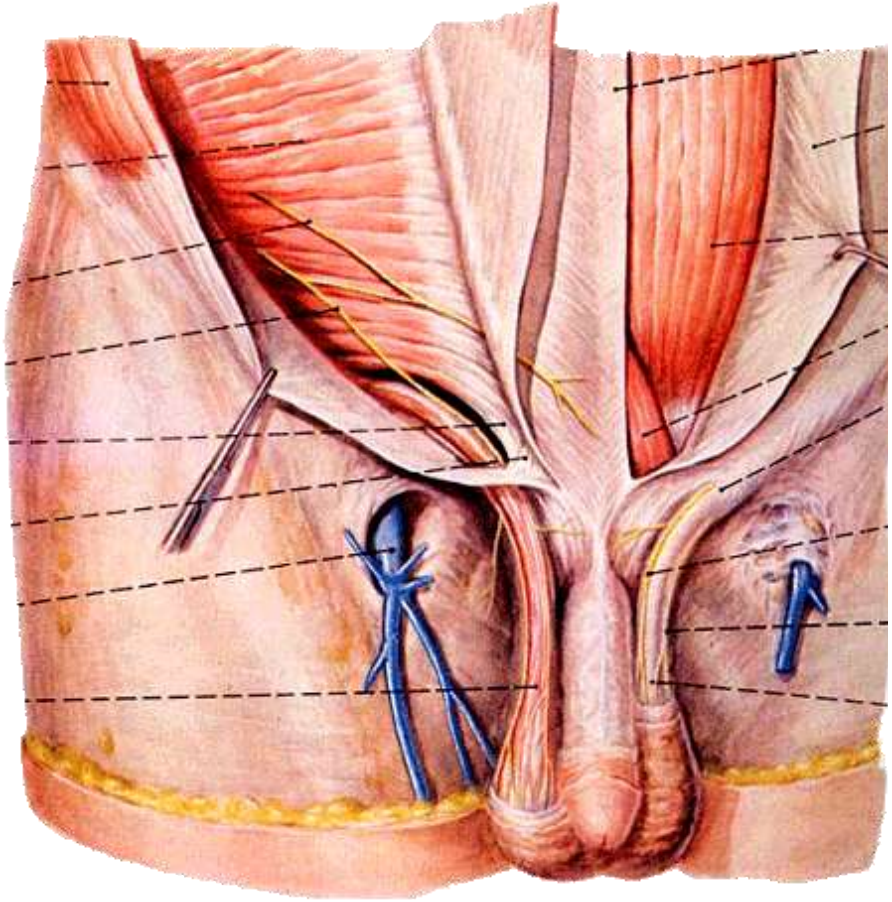

5、腹横筋膜

6、腹膜下筋膜

7、壁腹膜

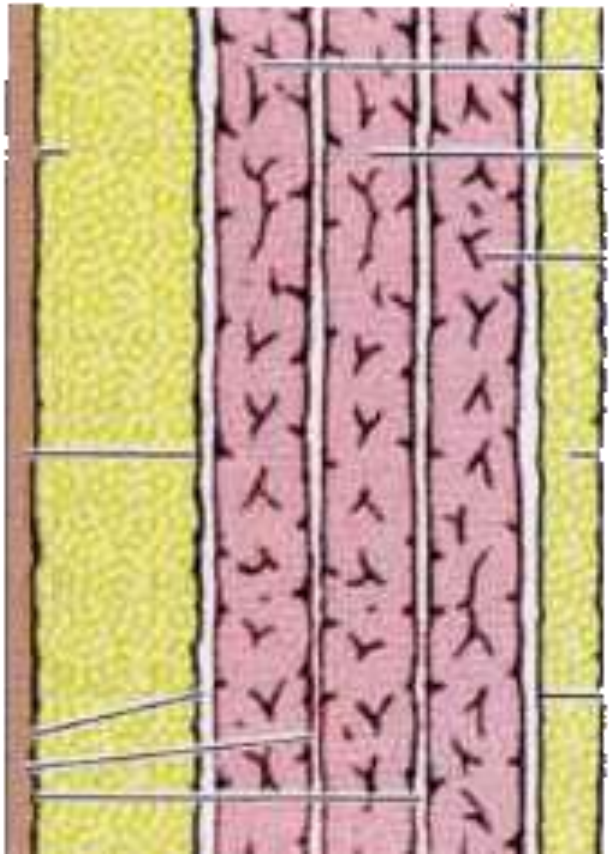

（二）阑尾

1、位置

- 根部连于盲肠后内侧壁（ Mcburney点）
- 三条结肠带下端汇聚续于阑尾根部

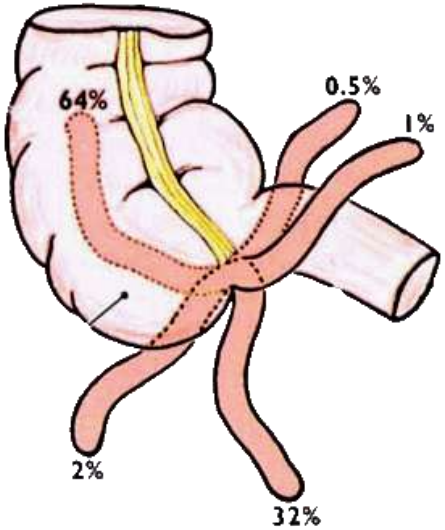

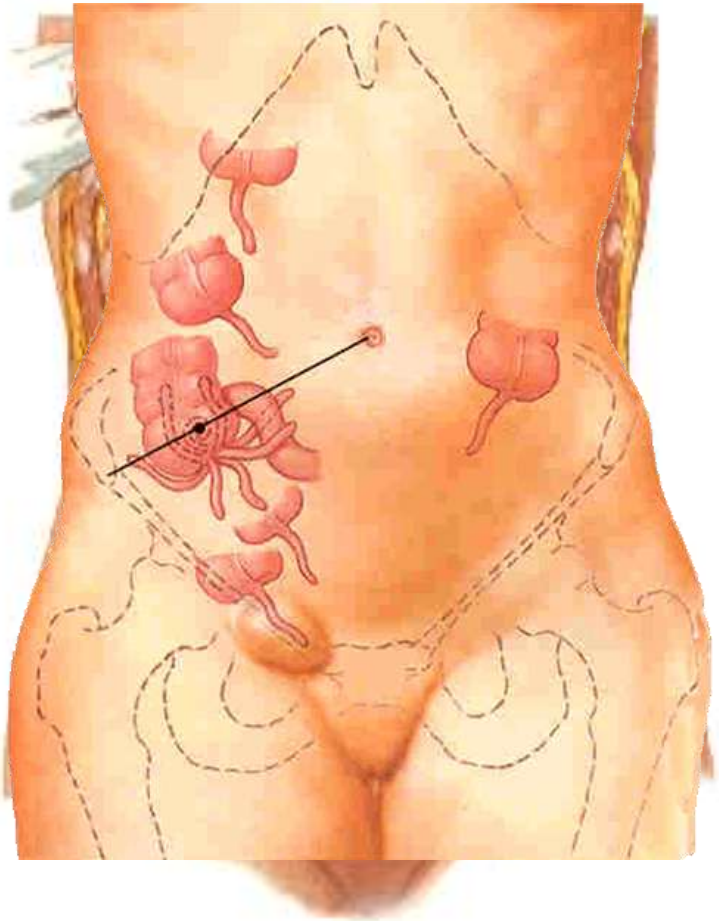

- 尖端位置游离

（1）盲肠后位：约24%

（2）盲肠下位：约6%

（3）盆位：约26%

（4）回肠前位：约28%

（5）回肠后位：约8%

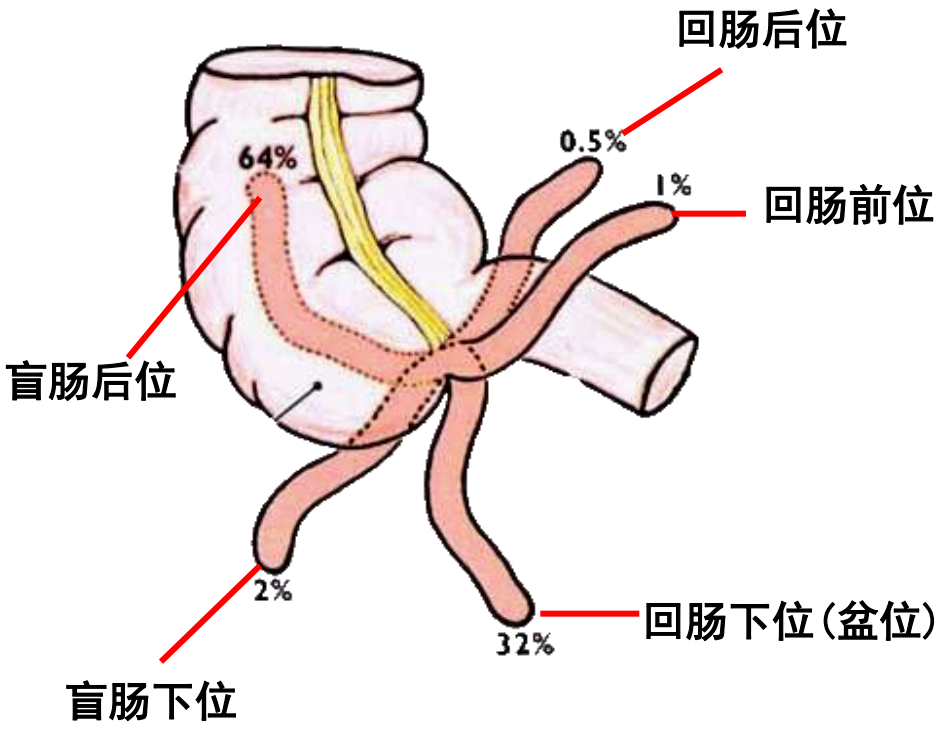

2、血管

- 回结肠动脉→阑尾动脉
- 阑尾静脉→回结肠静脉 →肝门静脉

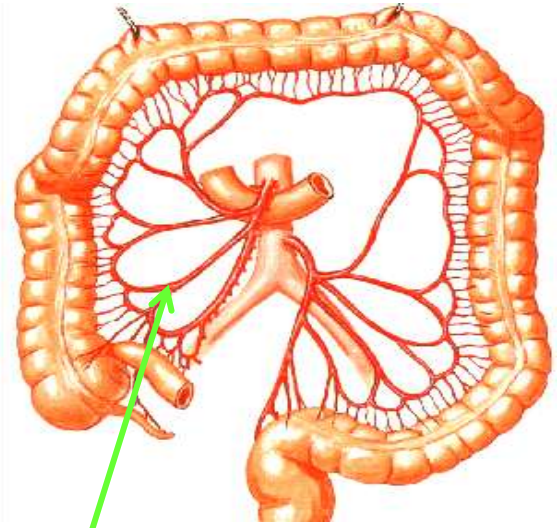

回结肠动脉

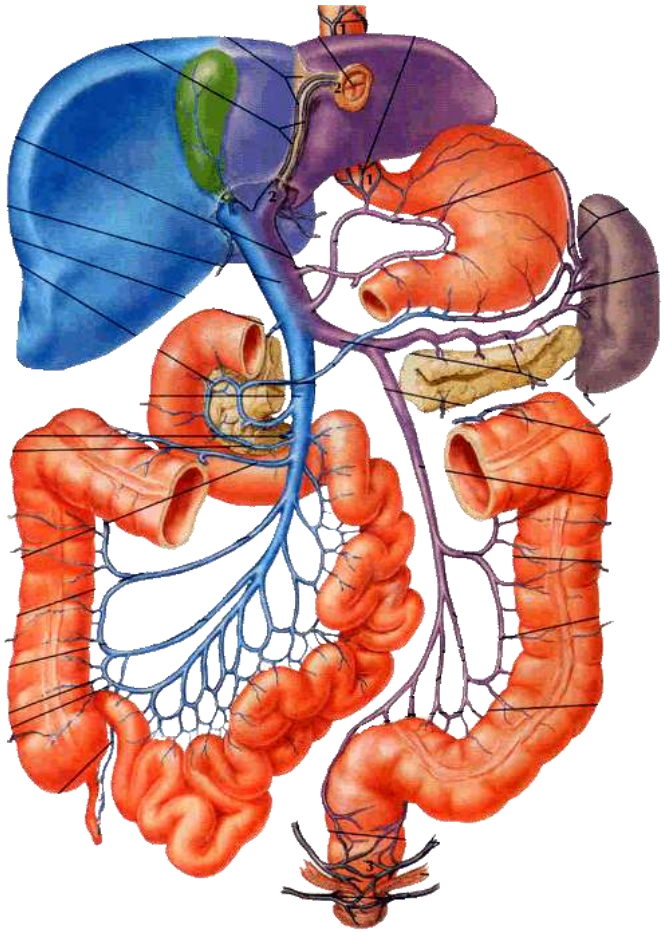

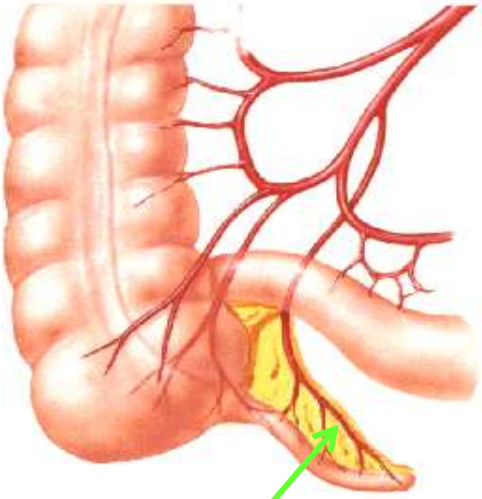

阑尾动脉

3、淋巴
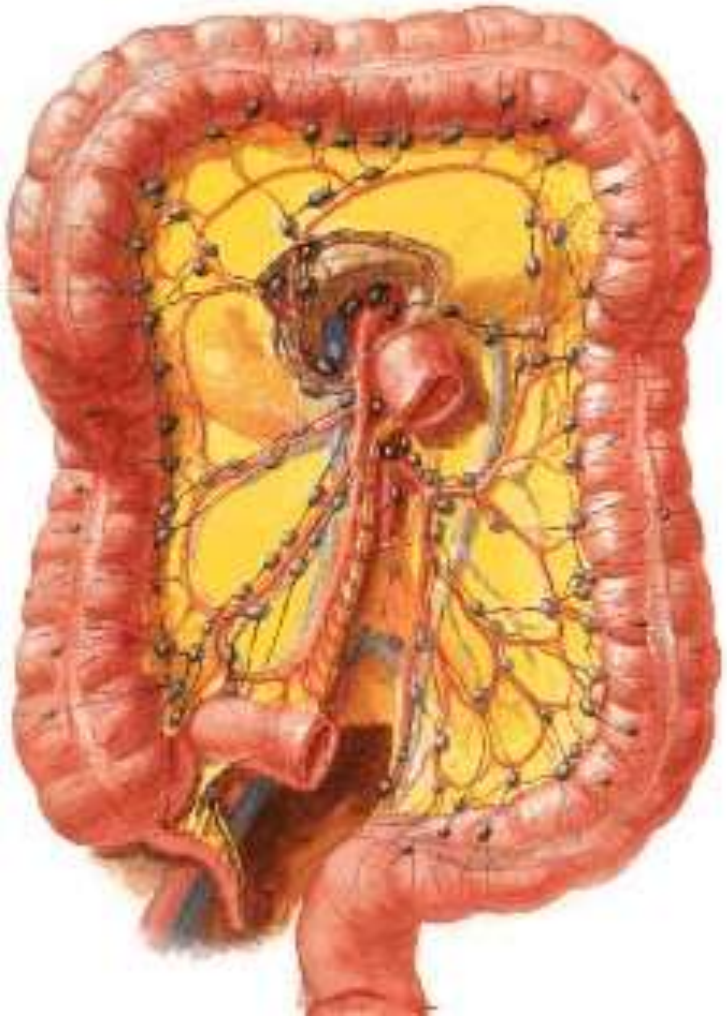
- 盲肠与阑尾的淋巴结多沿同名动脉排列→回结肠淋巴结→肠系膜上淋巴结